

Spasmodic Torticollis: The Dental Connection

Anthony B. Sims, D.D.S.; Brendan C. Stack, D.D.S., M.S.;
G. Gary Demerjian, D.D.S.

0886-9634/3003-
188\$0.25/pp, THE
JOURNAL OF
CRANIOMANDIBULAR
PRACTICE,
Copyright © 2012
by CHROMA, Inc.

Manuscript received
August 15, 2011; accepted
October 7, 2011

Address for correspondence:
Dr. Anthony B. Sims
8865 Stanford Boulevard,
Ste. 131
Columbia, Maryland 21045
Email:
absimsdds@hotmail.com

ABSTRACT: Spasmodic torticollis or cervical dystonia (CD) is the most common form of focal dystonia and is characterized by sustained abnormal muscle contractions in the head and neck area resulting in abnormal positioning or posturing of the head. The dystonic muscle spasms associated with spasmodic torticollis may affect any combination of neck muscles. Three cases are reported of spasmodic torticollis that were treated by a dental appliance with individual varying occlusal heights to open the maxillo-mandibular vertical dimension. Upon increasing the vertical dimension of occlusion, there was a slowing and/or discontinuance of the symptoms of cervical dystonia. The proposed hypothesis for this reversal is that there may be neuritis of the auriculotemporal branch of the trigeminal nerve, which has direct input into the reticular formation (RF), and it may activate the cells of the pontine region of the RF known for the control and deviation of head posture. There is growing clinical evidence that temporomandibular joint (TMJ) dysfunction may be a factor in this neurological and painful disorder when it coexists.

Dr. Anthony B. Sims *Dr. Anthony B. Sims received his D.D.S. degree from Ohio State University in 1983. Currently, he has a general dental practice in Columbia, Maryland, where he also treats TMD and snoring/sleep apnea patients. His research interest is in understanding how dentistry interrelates with the many different types of movement disorders. He is a member of the American Academy of Craniofacial Pain, National Spasmodic Torticollis Assoc., Reflex Sympathetic Dystrophy Syndrome Assoc., and The International Association for Orthodontics. He has spoken in the United States and Europe on the perspective dentistry has on the possible abeyance of certain movement disorders. He has published the results of his treatment in peer-reviewed journals. To view the discontinuance of movement disorders associated with Tourette's syndrome and other disorders go to <http://www.bodymovementdisorders.com>.*

What causes spasmodic torticollis or cervical dystonia? The short answer is that as of now clinicians are unsure. Some studies suggest that focal dystonia may be precipitated by trauma or overuse of the affected region of the body.¹⁻⁴ In some cases, dystonia has been linked to several apparent classes of causations, including genetics,⁵⁻⁷ brain trauma,^{8,9} adverse drug interactions (both legal and illegal),¹⁰ and/or severe peripheral nerve trauma.¹¹⁻¹³ Almost all dystonic movements share a directional quality that is typically sustained, and some movements may be prolonged. In general, the dystonias may be classified based on: the age at which symptoms first appear; the area or areas of the body that are affected (anatomical distribution); or the cause of the dystonia. CD is classified as a focal dystonia because it typically affects one area of the body (i.e., head and neck). These sustained muscle contractions or spasms result in head movements that may be jerky, periodic, or sustained. The resulting unnatural positioning of the head is usually referred to as dystonic posturing. One shoulder may be elevated and displaced forward on the side toward which the chin or head turns, **Figure 1**. In addition, the condition is often painful and there may be mild associated dystonia in the upper arm and/or upper back muscles

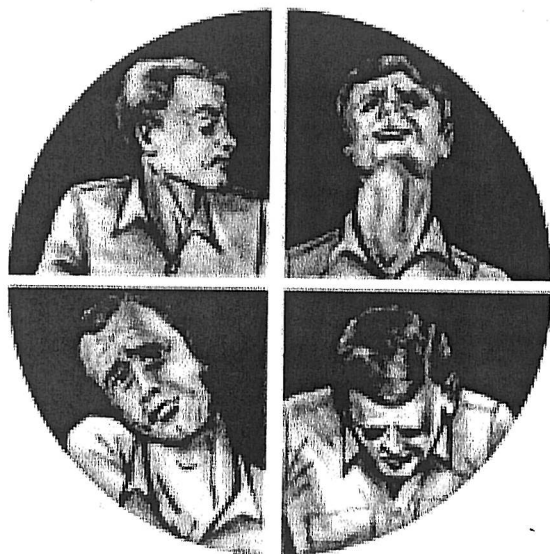


Figure 1
CD is characterized by the abnormal head and shoulder postures the protracted muscle spasms produce. The above images show four basic conditions that can develop, depending on which muscles are active. Clockwise from upper left, these are called Torticollis (rotated head position), Retrocollis (head pulled backward), Anterocollis (head pulled forward), and Laterocollis (head pulled to the side.) Combinations of these forms can also develop.

on the same side. However, in many patients, the relationship is less clear and trauma alone probably would not be sufficient for the development of a dystonia. In addition, CD is the most common focal dystonia that responds to a *sensory trick* or *geste antagoniste*.¹⁴⁻¹⁶ For example, patients with CD may find that placing a hand on the side of the face, chin, or the back of the head, temporarily alleviates the dystonic posture. Leaning the head back against a chair or placing a hand on the top of the head may also help to relieve CD symptoms. The reason that sensory tricks work for some patients and not others is not fully understood. One possible hypothesis is that the trigeminal nerve not only conveys pain/temperature impulses, but also carries touch and position feedback. As in allodynia, where the pain is due to a stimulus that does not normally produce pain, it may be that the primary sensory receptors for touch/position (Meissner's corpuscles, Merkel's receptors, Pacinian corpuscles, Ruffini's corpuscles, hair receptors, muscle spindle organs, Golgi tendon organs) are structurally different from the pain/temperature receptors such that the information is processed at an unconscious level (mainly by the cerebellum and the vestibular nuclei), therefore becoming an unrecognized factor in sensory tricks that correct the head's posture.

Materials and Methods

Three individual patients ages 60, 65, and 68 were diagnosed by their neurologists with torticollis: two women with right side rotational torticollis, and one male with right side lateral torticollis. The disorders began after a motor vehicle accident, a tennis court accident, and the third was of congenital origin. The symptoms of neck pain and pressure, headaches, shoulder pains, occipital pain, scoliosis, jaw pain, TMJ pain and dysfunction, back pain, dizziness, fatigue, muscle twitching, and sinus congestion were persistent for 25, 15, and 18 years. Numerous treatments have consisted of multiple oral medications, chiropractic treatment, baclofen injections, botulinum toxin injections, exercise programs, massage, rolfing, acupuncture, and others with varying degrees of success.

Each patient underwent a comprehensive oral and temporomandibular joint (TMJ) examination and evaluation. All three cases showed significant restricted and/or limited mandibular interincisal opening with deviation, evidence of bruxism of and/or missing posterior teeth. All underwent MR imaging of the TMJ and each patient showed a dislocation of the left, right, or both TMJ menisci. Patients were then measured for and had an oral orthotic made of stainless steel and acrylic placed over the mandibular teeth to the position that was determined to relieve all or most of their symptoms. All patients agreed to be videotaped. Within 20 minutes after placing the orthotic, the patients' head positions began to change to a more consistently normal position. Removal of the oral orthotics resulted in the head position returning to the torticollis position. Patients were instructed to wear orthotics 24/7, including while eating, and follow-up appointments were at 1-week, 1-month, 3-month and 6-month intervals or, at more frequent intervals as a patient expressed a desire to be seen. At each interval, the patient's head position was improved or remained constant in its normal position.

Discussion

The mean age of symptom onset in patients with cervical dystonia is approximately 41 years. However, onset is variable and may range from childhood to old age. Women are more commonly affected by CD than men, in a ratio of 2:1.

There are several theories that researchers present, such as genetic predisposition, physical trauma, or even psychological trauma. Though not life threatening, the social implications are very profound. One area that has not been totally explored is the aspect of peripheral nerve

trauma. It is suspected that certain kinds of peripheral nerve injuries can alter sensory nerve transmissions into the brain in such a way as to trigger unwanted muscle actions.

There are many studies which link malfunction of the TMD or craniocervical mandibular disorders to multiple symptoms, including but not limited to tinnitus, Meniere's disease, decreased hearing, aural fullness, headaches, dizziness, difficulty balancing, difficulty swallowing, neck and shoulder soreness, cracking and clicking sounds in the jaw joints, limited mouth opening, visual disturbances and, in some cases, neurological disorders.^{17,18} Many of these sources also cite cervical spine malfunction as being a contributing and correlating factor in TMD. The issue is whether TMD is a result of cervical spine malfunction or vice versa.

The answer is unclear as to whether cervical spine malfunction is an etiology of TMD dysfunction (TMD) or vice versa in these cases. There are patients that exhibit no cervical spine malfunction and have TMD. Connections have been shown radiographically that patients with atlas/axis subluxation show a malalignment of the TMD and a derangement of the mandible. The rotated or altered head position that articulates (Figure 2) with the cervical spine may result in nonalignment or disarticulation of the TMD within the glenoid fossa. There are over 150 muscles and ligaments in the head and neck, which are used in the process of eating and when the TMD joints are malfunctioning (either through muscle pain or internal derangement), the neck and shoulder muscles may go into painful spasm during this process. This is one of the hypotheses given for the etiology of spasmodic torticollis.

The most painful part may have nothing to do with the joints themselves, but may be due to muscular spasm in the trapezius and scalene muscles. The pain can be exacerbating and the symptoms vary.^{19,20}

Muscle hypertrophy is present in almost all CD patients.²¹⁻²³ Two-thirds to 80% of patients, particularly those with sustained head deviation, have associated neck pain. About one-third to 40% of these patients also experience head tremor (i.e., dystonic tremor), hand tremor, or both.^{24,25} Approximately 20% of patients with CD also have blepharospasm or dystonia in other muscles or in muscle groups of the arm or hand. In addition, about 15% of patients have hand tremors resembling essential tremor.²⁶

The close relationship of TMD to CSD warrants close scrutiny and certainly collaboration between physicians and physical therapists or chiropractors experienced in upper cervical analysis and adjustment, and dentists experienced in TMD. However, in many patients, the

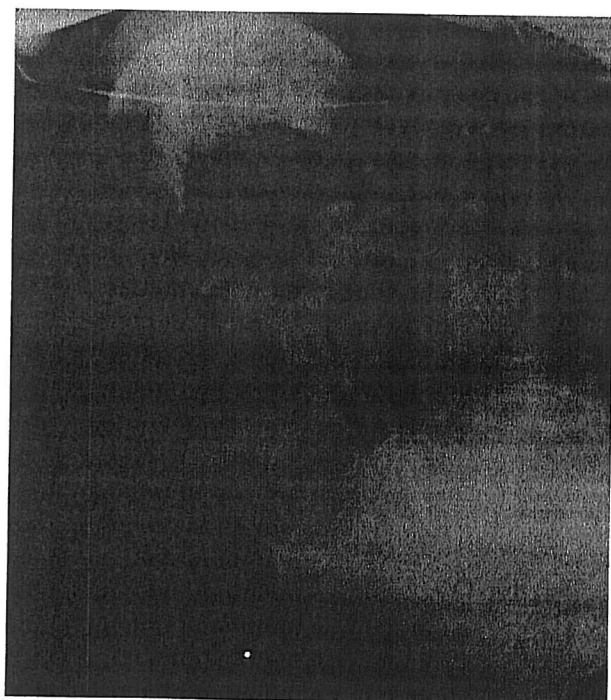


Figure 2 X-ray showing the head out of alignment, which results in nonalignment or disarticulation of the TMD in the glenoid fossa.

The most common cause of neck pain results from weakened muscles and poor posture.²⁷ A forward head posture results in strain of the posterior muscles of the neck. This is commonly observed while driving, working on a computer, talking on a telephone or sitting at a desk. The pain is felt as a tight aching painful sensation in the back of the neck and shoulders. Commonly, this pain is felt as facial pain or a headache that comes up the back of the head and into and around the eyes. What is not frequently realized is that many of the muscles of the anterior neck control the jaw and tongue. Pain in these muscles can refer pain into the face and teeth and can feel like swollen glands or a lump in the throat. This can give the voice hoarseness and cause difficulty in swallowing. Additionally, the trigeminal nerve that innervates the jaw muscles and TMD also commingles with the nerves of the neck.²⁸ Therefore, dysfunction within cervical structures commonly leads to problems within the jaw and vice versa.

The most common cause of neck pain results from weakened muscles and poor posture.²⁷ A forward head posture results in strain of the posterior muscles of the neck. This is commonly observed while driving, working on a computer, talking on a telephone or sitting at a desk. The pain is felt as a tight aching painful sensation in the back of the neck and shoulders. Commonly, this pain is felt as facial pain or a headache that comes up the back of the head and into and around the eyes. What is not frequently realized is that many of the muscles of the anterior neck control the jaw and tongue. Pain in these muscles can refer pain into the face and teeth and can feel like swollen glands or a lump in the throat. This can give the voice hoarseness and cause difficulty in swallowing. Additionally, the trigeminal nerve that innervates the jaw muscles and TMD also commingles with the nerves of the neck.²⁸ Therefore, dysfunction within cervical structures commonly leads to problems within the jaw and vice versa.

Most treatments are aimed at restoring normal anatomy, encouraging normal range of motion of the joints and muscles, within the neck and decreasing or eliminating all aggravating factors.^{29,30} Surgery is only indicated where there is clear evidence that a disc or vertebrae remains out of place and continues causing pain and dysfunction. More conservative treatments should be attempted initially.

At the present time, the first line of treatment is botulinum toxin injected into various muscles by a neurologist. This blocks the release of acetylcholine from the neuromuscular junction effectively weakening the muscles for a period of 3-4 months. The process must then be reapplied. The disadvantage is that over time the body can become immune to the toxin and the toxin becomes non-effective. The second is denervation neck surgery which essentially cuts the nerves to the muscle which allows for possible correction of the torticollis. The disadvantage to this procedure is that it is non-reversible and sometimes there is numbness in the back of the head, some remaining movements, difficulty swallowing, and there may be a lack of benefit. The third treatment is deep brain stimulation surgery (DBS) in which two electrodes are placed into the basal ganglia or globus pallidus to control the movement disorder. This procedure is used mainly for general dystonia's but also for those who do not respond to any of the other treatments and it is only 50% effective. This too is irreversible and requires a second surgery to implant a battery-operated medical device called a neurostimulator. The amount of reduction varies from patient to patient and the patient still has to take medications after the surgery. We propose an alternative treatment with a specifically made oral orthotic

that increases the vertical dimension and decrease neuropathy within the TM joint, and thus the syndrome of cervical dystonia may diminish or discontinue.

Research has shown that when the auriculotemporal nerve in the TMJ is stimulated, there is motor activity of the sternocleidomastoid and splenius muscle of the neck.^{31,32} This stimulus travels via primary afferent fibers of the auriculotemporal nerve to the brainstem and an area called the reticular formation.^{33,34} Within certain areas of the reticular formation, particularly the medial pontine reticular formation, are nerves that when stimulated cause the head and neck muscles to turn toward the same side as the stimulation.^{35,36} The etiology for spasmodic torticollis may be that these reticular formation nerves are being constantly bombarded by excessive stimuli originating in over-stimulated nerves of the TMJ. With a constant stimulation of the auriculotemporal nerve, possibly caused by some type of periauricular trauma or injury (i.e., an internal derangement of the temporomandibular joint), the aberrant signal may be causing the head and neck to turn to the ipsilateral side of the stimulation. When the stimulus is relieved from the TMJ, the stimulus in the reticular formation is relieved, which then relieves the turning of the head to that side.³⁷

Conclusion

Precision orthotics made by a dentist can help to relieve the noxious nerve stimulation within the TMJ without drugs and/or surgery. During initial evaluation patients are usually given a prescription for an MR appliance for the TM joints to determine if there is any internal derangement.

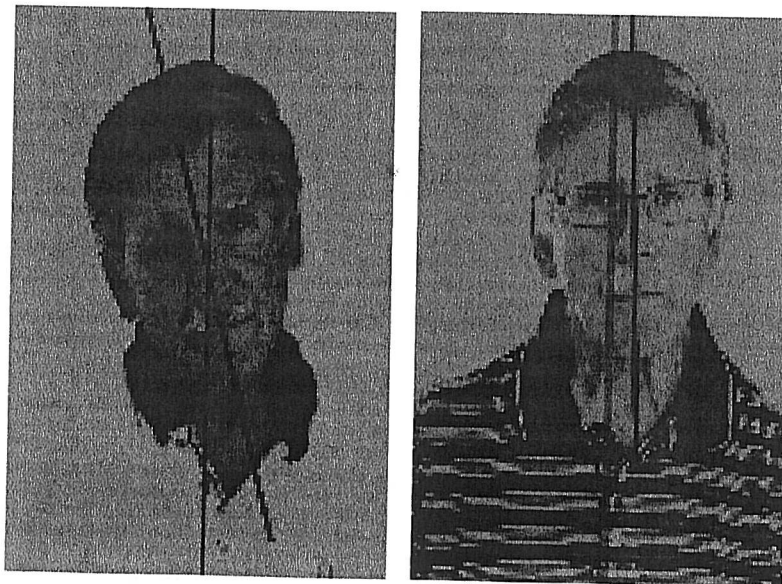

Figure 3
Use of a tailored oral orthotic to reposition this patient's head. The TMJ has reduced muscle spasm severity and improved both posture and head mobility.



its in nonalign-
sa.

probably may
ystonia. Some
ne role in trig-
gistering suscep-

results from
forward head
muscles of the
ving, working
ting at a desk.
nsation in the
y, this pain is
up the back of
at is not fre-
s of the ante-
ain in these
eeth and can
eat. This can
alty in swal-
at innervates
les with the
within cervi-
ithin the jaw

ment of one or both joints. In a majority of the cases that are treated in this manner, it is found that there is compression within the joints causing an inflammation or internal trauma to the tissues due to the internal derangement. This neuroinflammation may be one of the underlying factors of the disorder. When the compression is relieved by the orthotic, there is a gradual discontinuance of the spasmodic torticollis, and the muscles of the head and neck begin to return to normal with a decrease in pain. This has been done in a number of cases, and tremendous relief for patients was accomplished. See **Figure 3** for an example of one ST patient's improvement from the use of an orthotic.

Trials are still being done in this field and continued research is needed. It is an alternative treatment for ST, but the success rate is good for those with well-defined TMJ disorders. Significantly, treatment with TMJ orthotics is fully compatible with established treatments, including botulinum toxin injections, muscle relaxants, baclofen injections for pain, and various kinds of physical therapy. Patients may find some combination of treatments will provide maximum relief.

Acknowledgements

The authors wish to acknowledge, and are grateful for, the assistance of the National Spasmodic Torticollis Association and its president Ken Price in the preparation of this manuscript and their support in the development of this study. To learn more about this treatment for spasmodic torticollis and other dental/movement disorder connections, you can visit Dr. Anthony Sims's website (www.absimsdds.com) and click the testimonial section, Dr. Brendan Stack's (www.tmjstack.com), or Dr. Gary Demerjian's (www.tmjsleeptherapy.com).

References

1. Frei KP, Pathak M, Jenkins S, Truong DD: Natural history of posttraumatic cervical dystonia. *Mov Disord* 2004; 19(12):1492-1498.
2. Crowner BE: Cervical dystonia: disease profile and clinical management. *Phys Ther* 2007; 87(11):1511-1526. Epub 2007 Sep 18.
3. Asmus F, von Coelln R, Boertlein A, Gasser T, Mueller J: Reverse sensory geste in cervical dystonia. *Mov Disord* 2009; 24(2):297-300.
4. Yaman M, Sahin S, Kiziltan ME: Blink reflex recovery in central and peripherally originated movement disorders of the cranio-cervical area: a comparative study. *Electromyogr Clin Neurophysiol* 2009; 49(1):19-25.
5. Zhang SS, Fang DF, Hu XH, Burgunder JM, Chen XP, Zhang YW, Shang HF: Clinical feature and DYT1 mutation screening in primary dystonia patients from South-West China. *Eur J Neurol* 2010; 17(6):846-851, Epub 2010
6. Shanker V, Bressman SB: What's new in dystonia? *Curr Neurol Neurosci Rep* 2009; 9(4):278-284.
7. Hasegawa K, Toyoshima I: [Causative gene and its associated gene for Parkinson disease and dystonia]. *Brain Nerve* 2009; 61(4):447-463.
8. Lo SE, Rosengart AJ, Novakovic RL, Kang UJ, Shah DN, Khan MA, Dalvi A, Goldenberg FD, Macdonald RL, Frank JI: Identification and treatment of cervical and oromandibular dystonia in acutely brain-injured patients. *Neurocrit Care* 2005; 3(2):139-145.

9. Kawasaki MS, Hernández-Fustes OJ, Scheer Neto EJ, Hernández-Cossio O: [Post-traumatic spasmodic torticollis]. *Arq Neuropsiquiatr* 1998; 56(2):300-306.
10. Yumru M, Savas HA, Selek S, Savas E: Acute dystonia after initial doses of ziprasidone: a case report. *Prog Neuropsychopharmacol Biol Psychiatry* 2006; 30(4):745-747, Epub 2006 Mar 6.
11. Schrag A, Bhatia KP, Quinn NP, Marsden CD: Atypical and typical cranial dystonia following dental procedures. *Mov Disord* 1999; 14(3):492-496.
12. Velickovic M, Benabou R, Brin MF: Cervical dystonia pathophysiology and treatment options. *Drugs* 2001; 61(13):1921-1943.
13. O'Riordan S, Hutchinson M: Cervical dystonia following peripheral trauma—a case-control study. *J Neurol* 2004; 251(2):150-155.
14. Ochudlo S, Drzyzga K, Drzyzga LR, Opala G: Various patterns of gestes antagonistes in cervical dystonia. *Parkinsonism Relat Disord* 2007; 13(7):417-420, Epub 2007 Mar 13.
15. Schramm A, Reiners K, Naumann M: Complex mechanisms of sensory tricks in cervical dystonia. *Mov Disord* 2004; 19(4):452-458.
16. Naumann M, Magyar-Lehmann S, Reiners K, Erbguth F, Leenders KL: Sensory tricks in cervical dystonia: perceptual dysbalance of parietal cortex modulates frontal motor programming. *Ann Neurol* 2000; 47(3):322-328.
17. Matheus RA, Ramos-Perez FM, Menezes AV, Ambrosano GM, Haiter-Neto F, Bóscolo FN, de Almeida SM: The relationship between temporomandibular dysfunction and head and cervical posture. *J Appl Oral Sci* 2009; 17(3):204-208.
18. Shiau YY, Chai HM: Body posture and hand strength of patients with temporomandibular disorder. *J Craniomandib Pract* 1990; 8(3):244-251.
19. Kondo E, Aoba TJ: Case report of malocclusion with abnormal head posture and TMJ-symptoms. *Am J Orthod Dentofacial Orthop* 1999; 116(5):481-493.
20. Gray AR, Barker GR: Idiopathic blepharospasm-omandibular dystonia syndrome (Meige's syndrome) presenting as chronic temporomandibular joint dislocation. *Br J Oral Maxillofac Surg* 1991; 29(2):97-99.
21. Factor SA, Lew MF, Trosch RM: Current and emerging treatments for cervical dystonia. *CNS Spectr* 2000; 5[6 Suppl 5]:S1-8.
22. Lee LH, Chang WN, Chang CS: The finding and evaluation of EMG-guided BOTOX injection in cervical dystonia. *Acta Neurol Taiwan* 2004; 13(2):71-76.
23. Wright RA, Ahlskog JE: Focal shoulder-elevation dystonia. *Mov Disord* 2000; 15(4):709-713.
24. Pal PK, Samii A, Schulzer M, Mak E, Tsui JK: Head tremor in cervical dystonia. *Can J Neurol Sci* 2000; 27(2):137-142.
25. Deuschl G, Heinen F, Guschlbauer B, Schneider S, Glocker FX, Lütting CH: Hand tremor in patients with spasmodic torticollis. *Mov Disord* 1997; 12(4):547-552.
26. Lou JS, Jankovic J: Essential tremor: clinical correlates in 350 patients. *Neurology* 1991; 41[2 (Pt 1)]:234-238.
27. Sa DS, Mailis-Gagnon A, Nicholson K, Lang AE: Posttraumatic painful torticollis. *Mov Disord* 2003; 18(12):1482-1491.
28. Serrao M, Rossi P, Parisi L, Perrotta A, Bartolo M, Cardinali P, Amabile G, Pierelli F: Trigemino-cervical-spinal reflexes in humans. *Clin Neurophysiol* 2003; 114(9):1697-1703.
29. Comella CL, Jankovic J, Brin MF: Use of botulinum toxin type A in the treatment of cervical dystonia. *Neurology* 2000; 55[12 Suppl 5]:S15-21.
30. Goldman S, Ahlskog JE: Posttraumatic cervical dystonia. *Mayo Clin Proc* 1993; 68(5):443-448.
31. Tecco S, Tetè S, D'Attilio M, Perillo L, Festa F: Surface electromyographic patterns of masticatory, neck, and trunk muscles in temporomandibular joint dysfunction patients undergoing anterior repositioning splint therapy. *Eur J Orthod* 2008; 30(6):592-597, Epub 2008 Nov 5.
32. Jiang T, Yang Z, Zhang Z, Feng H: [Electromyography activities of the head, neck and upper trunk muscles with mandibular movement in normal adults]. *Zhonghua Kou Qiang Yi Xue Za Zhi* 2002; 37(6):431-434.
33. Pinto ML, Olyntho-Tokunaga HH, Souccar C, Schoorlemmer GH, Lapa Rde C: The interstitial system of the trigeminal spinal tract projects to the red nucleus in mice. *Somatosens Mot Res* 2007; 24(4):221-225.
34. Mainero C, Zhang WT, Kumar A, Rosen BR, Sorensen AG: Mapping the spinal and supraspinal pathways of dynamic mechanical allodynia in the human trigeminal system using cardiac-gated fMRI. *Neuroimage* 2007; 35(3):1201-1210, Epub 2007 Feb 4.
35. Siegel JM, Tomaszewski KS: Behavioral organization of reticular formation: studies in the unrestrained cat. I. Cells related to axial, limb, eye, and other movements. *J Neurophysiol* 1983; 50(3):696-716.
36. Davidson AG, Buford JA: Bilateral actions of the reticulospinal tract on arm and shoulder muscles in the monkey: stimulus triggered averaging. *Exp Brain Res* 2006; 173(1):25-39, Epub 2006 Feb 28.
37. Sims A, Stack B: Tourette's syndrome: a pilot study for the discontinuance of a movement disorder. *J Craniomandib Pract* 2009; 27(1):11-18.

Dr. Brendan C. Stack is an orthodontist who has limited his practice to orthodontics, craniofacial pain, and TMJ disorders for the past 42 years. Having graduated from Georgetown University, he is also the Tufts' University 2003 recipient of the "Lifetime Achievement Award" for his years of contribution to the field of craniofacial pain. In the United States and Europe, he is frequently an invited lecturer on the topics of TMJ and craniofacial pain. He has published peer-reviewed literature on the long-term results of his treatment procedures. He has contributed chapters to TMJ textbooks and written numerous articles and manuals on the diagnosis and treatment planning of craniofacial pain patients and has also produced videotapes of his treatment technique to teach other doctors. Dr. Stack is a founding member and was the first president of the American Academy of Craniofacial Pain and is a diplomate of the American Board of Craniofacial Pain. He is a member of the International Headache Society, the American Pain Society, and the American Association of Orthodontics.

Dr. G. Gary Demerjian received his D.D.S. degree from the University of the Pacific in 1990. He is a general dentist currently practicing in Glendora and Burbank California. His practice is primarily focused on the treatment of TMJ and craniofacial disorders. He currently holds a Diplomate with the American Board of Craniofacial Pain, the American Academy of Pain Management, and the American Board of Forensic Dentistry, and he is also a Fellow in the American Academy of Craniofacial Pain and the International College of Cranio-Mandibular Orthopedics. He has spoken in the United States on the subjects of TMJ, craniofacial pain, and systemic correlates. The results of his treatments have been published in peer-reviewed journals.
